

Chest Radiography for Radiologic Technologists



©2009 ASRT. All rights reserved.

asrt

American Society of Radiologic Technologists

Chest Radiography for Radiologic Technologists

DAN L. HOBBS, M.S.R.S., R.T.(R)(CT)(MR)

Multiple sclerosis (MS) is a chronic inflammatory disorder of the central nervous system that usually first affects people in their 20s or 30s. MS is one of the most common causes of nontraumatic disability among young and middle-aged individuals. Because symptoms of MS are extremely variable and often quite subtle, the use of magnetic resonance (MR) imaging plays a crucial role in diagnosis and management. Early diagnosis and treatment can slow the progression and limit the impact of this potentially devastating disease.

This ASRT Directed Reading Classic was originally published in Radiologic Technology, July/August 2007, Vol. 78/No. 6.

Visit www.asrt.org/store to purchase other ASRT Directed Reading Classics.

After completing this article, the reader should be able to:

- Identify the basic anatomy seen on a chest radiograph.
- Describe the anatomical relationships of various organs in the chest.
- Describe the basic positioning requirements for a chest exam.
- List the criteria used to critique a chest radiograph.
- Identify radiologists' requirements for interpreting a chest radiograph.
- Discuss several common disease processes of the lungs and their radiographic appearances.
- Evaluate a chest radiograph for various devices such as endotracheal tubes, chest tubes and central venous catheters.
- Describe several pathologies of the chest.

Chest radiography is the most common radiographic procedure performed in medical imaging departments, and one of the most often repeated exams.¹⁻³ It is estimated that in the United States 68 million chest radiographs are performed each year.⁴ Chest radiography is performed to evaluate the lungs, heart and thoracic viscera.

Additionally, disease processes such as pneumonia, heart failure, pleurisy and lung cancer are common indications. The American College of Radiology (ACR) and others suggest that daily chest radiographs are indicated for critically ill patients.⁵⁻⁷ This includes patients on ventilators, as well as those with acute cardiopulmonary problems. According to the ACR Practice Guidelines for the Performance of Pediatric and Adult Chest Radiography, there are several indications for a chest radiograph.⁵ Some of these indications include:

- Evaluation of signs and symptoms potentially related to the respiratory, cardiovascular and upper gastrointestinal systems, as well as the

musculoskeletal system of the thorax. The chest radiograph also can help to evaluate thoracic disease processes, including systemic and extrathoracic diseases that secondarily involve the chest. Because the lungs are a frequent site of metastases, chest radiography can be useful in staging extrathoracic, as well as thoracic, neoplasms.

- Follow-up of known thoracic disease processes to assess improvement, resolution or progression.
- Monitoring of patients with life-support devices and patients who have undergone cardiac or thoracic surgery or other interventional procedures.
- Compliance with government regulations that mandate chest radiography. Examples include surveillance posteroanterior chest radiographs for active tuberculosis or occupational lung disease or exposures and other surveillance studies required by public health law.
- Preoperative radiographic evaluation when cardiac or respiratory

symptoms are present or when there is significant potential for thoracic pathology that could compromise the surgical result or lead to increased perioperative morbidity or mortality.⁵

The radiographer's role is to provide the physician with an image of the chest that is diagnostic and aids in the treatment of the patient. This cannot be accomplished satisfactorily without adequate knowledge of chest anatomy, pathology and consistent positioning in both the ambulatory and bedridden patient.

Normal Chest Anatomy

The Bony Thorax

The bony thorax of the chest is composed of the sternum anteriorly and 12 pairs of ribs that surround the lungs. Each pair of ribs connects to a corresponding thoracic vertebra posteriorly. The posterior rib attachments connect at the costovertebral and costotransverse joints. Each rib wraps around the lung and descends approximately 3 to 5 inches from its highest point posteriorly.² (See Figure 1.) The anterior portion of each rib connects by way of costocartilage to the sternum. The costocartilage usually does not show up on a radiograph unless it is calcified. The true ribs, numbers 1 through 7, connect anteriorly to the sternum by way of this costocartilage. (See Figure 2) The false ribs are numbers 8 through 12. Ribs 8 through 10 connect to the sternum by way of the costocartilages of the seventh ribs. False ribs 11 and 12 are short and do not wrap around the body; they also are called floating ribs. The ribs collectively provide a protective framework for the lungs.

The Respiratory System

The respiratory system is composed of the larynx, trachea, bronchi and lungs. The larynx, commonly referred to as the voice box, is the most superior structure in the respiratory system and houses the vocal cords. In close proximity to the larynx are the thyroid cartilage, laryngeal prominence or Adam's apple, and the cricoid cartilage. The epiglottis also is located nearby and acts as a covering for the trachea when food is swallowed. The trachea descends inferiorly beginning at about the level of C5 to approximately T5 or T6, where it bifurcates at the carina into the right and left primary bronchi. The bronchi then subdivide into several branches. Three secondary branches feed the right lung and 2 secondary branches feed the left lung. These branches divide into tertiary levels and smaller segments, eventually ending in the terminal bronchioles where the alveoli exchange oxygen and carbon dioxide.²

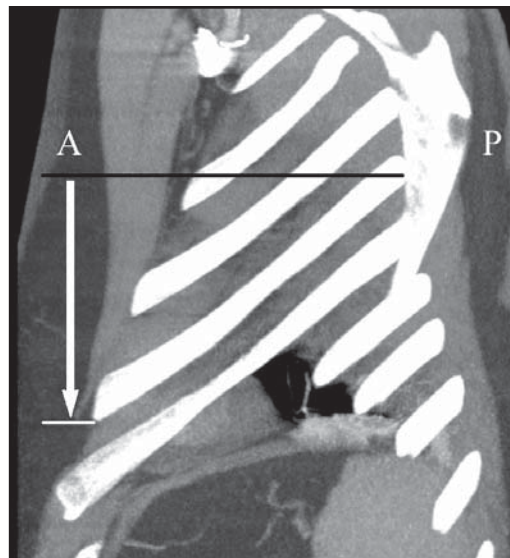

Figure 1. Sagittal CT image of the chest. This reformatted image demonstrates the posterior (P) to anterior (A) descent of the ribs as they wrap around the body. The distance between the 2 lines represented by the arrow is approximately 3 to 5 inches in most individuals.

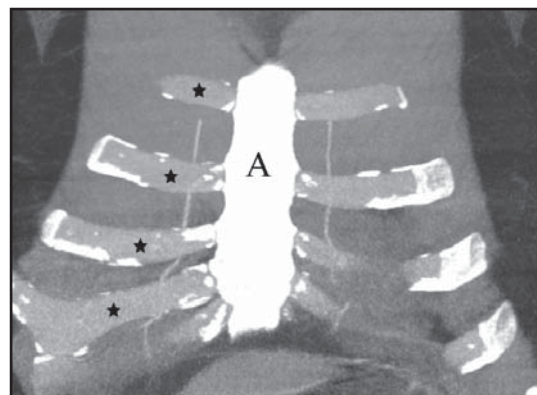


Figure 2. Coronal CT image of the anterior chest. This reformatted image of the anterior chest demonstrates the sternum (A). The stars indicate a few of the anterior ribs, which are composed of costocartilage. The anterior ribs do not appear on chest radiographs unless they are calcified. Note the calcifications that have formed on the proximal and distal segments of the costocartilages in this example.

The Lungs

The lungs are composed of a spongy material called the parenchyma. The parenchymal tissue contains the fine structures of the bronchial trees and pulmonary circulation. The exchange of oxygen and carbon dioxide takes